

# Pseudogranular Cell Tumor Of The Skin

D Sarma, E Santos, W Hunter, Z Gatalica

## Citation

D Sarma, E Santos, W Hunter, Z Gatalica. *Pseudogranular Cell Tumor Of The Skin*. The Internet Journal of Dermatology. 2006 Volume 5 Number 1.

## Abstract

A skin biopsy from a nasal lesion showed a dermal infiltrating neoplasm composed of polygonal cells with small nuclei and abundant coarsely granular eosinophilic cytoplasm.

Light microscopic features were that of a granular cell tumor. However, the results of the immunohistologic studies and the observations of the electron microscopic studies did not identify the nature of the cells nor did they confirm that it was a granular cell tumor.

We interpret the lesion as a pseudogranular cell tumor of the skin.

## SOURCE OF SUPPORT

None

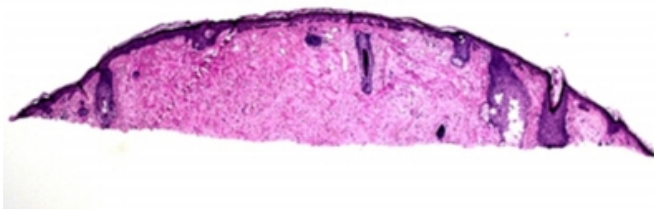## REPORT OF A CASE

A 66-year-old white female presented with a painless skin papule located on the right side of her nose that had been present for unknown period of time. There were no other symptoms and her past medical history was unremarkable.

The biopsied skin lesion showed an intact normal epidermis. The dermis showed a proliferation of polygonal cells with abundant coarsely granular eosinophilic cytoplasm and small round or ovoid nuclei (Figs. 1 and 2) leading to an impression of a granular cell tumor.

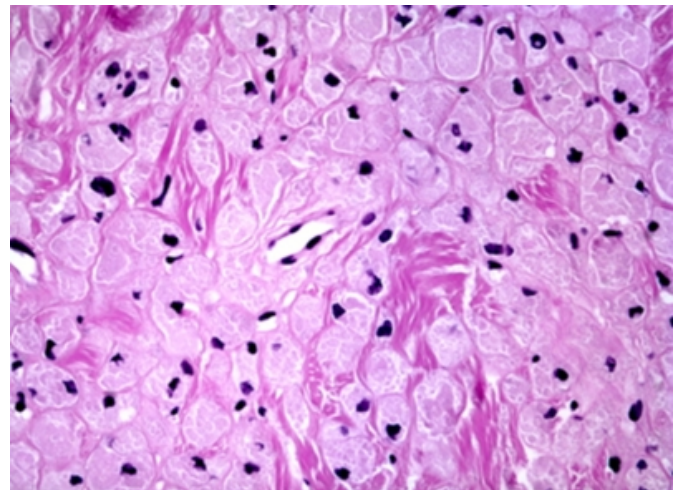
## Figure 1

Figure 1: Dermal proliferation of polygonal cells with eosinophilic granular cytoplasm (low power).



## Figure 2

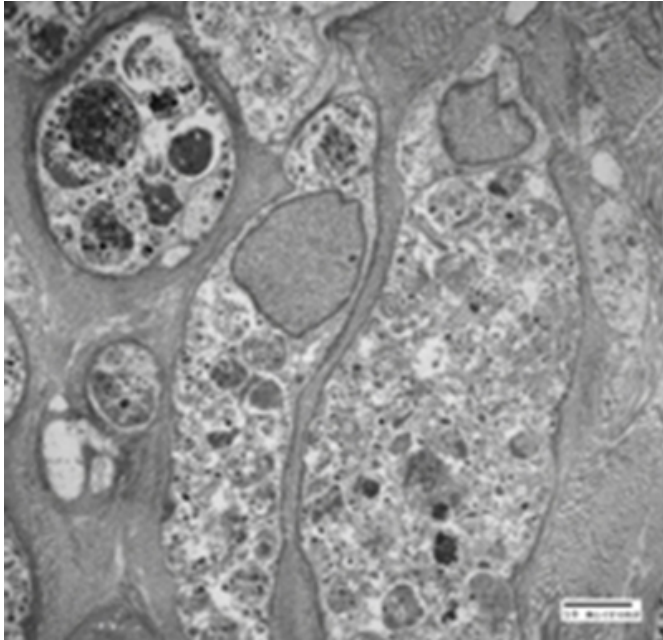
Figure 2: High power view of the tumor.



Immunohistochemical stains showed that the tumor cells were positive for CD34, CD68, and vimentin and negative for S100 protein, Melan A, HMB45, Factor VIIIa, pancytokeratin, desmin, and SMA. Ultrastructurally (Fig. 3), the dermal polygonal cells showed numerous intracytoplasmic phagosome-like vesicles, many containing electron-dense irregular material. The mitochondria and endoplasmic reticulum were scarce. The cells did not show any features of melanocyte, Schwann cell or classic mitochondria-rich granular cells.

### Figure 3

Figure 3: Electron microscopic picture showing numerous cytoplasmic phagosome-like vesicles. Mitochondria are scarce. No melanosomes or dense core granules are seen. 5000X.



### COMMENT

Granular cell tumors are neural-derived tumors commonly arising in the upper aerodigestive tract and skin. A typical granular cell tumor of the skin is composed of polyhedral cells with large amount of granular eosinophilic cytoplasm involving the dermis. The cells are typically immunoreactive for S-100 protein signifying a neural origin and are negative for epithelial, muscle, and endothelial markers [1].

In our case, the polygonal dermal cells with eosinophilic granular cytoplasm, on immunostains, are not suggestive of a neural, melanocytic, epithelial, or smooth muscle origin. Electron microscopic observation of a lack of abundant lysosomes is unlike that of a granular cell tumor. Other primitive mesenchymal cell tumors may present as a

granular cell proliferations. The CD34 and CD68 reactivity in our case may suggest that the polygonal cells are fibroblastic in origin. CD-34 positive and S-100 negative granular cell dendrocytosis has been described as a congenital lesion [2]). Another possibility considered was a possible oncocytic change in a dermal melanocytic nevus [3]. However,

the cells in such cases are S-100 positive and ultrastructurally they show numerous mitochondria near the melanosomes. Other non-neural tumors showing nonspecific granular change include dermatofibroma, fibroxanthoma, leiomyoma, leiomyosarcoma, angiosarcoma, and basal cell carcinoma [4]. Our case did not show any microscopic, immunohistochemical, or ultrastructural features of any of these tumors. The true origin of our tumor has not been established with certainty. Some of the nuclear changes observed in the ultrastructural study may be indicative of apoptosis and the granular changes in the cytoplasm may represent degenerative changes.

Pseudogranular cell tumor may be a reasonable descriptive name for such a lesion.

### CORRESPONDENCE TO

Deba P Sarma, MD Department of Pathology Creighton University Medical Center Omaha, NE 68131 Tel: 402-449-4951 debasarma@creighton.edu

### References

1. Ordonez NG. Granular cell tumor: a review and update. *Adv Anat Pathol.* 1999 Jul; 6(4):186-203.
2. Chang SE, Choi JH, Sung KJ, Moon KC, Koh JK, Lim SD, Huh J, Shwayder T, Lee MW. Congenital CD34-positive granular cell dendrocytosis. *J Cutan Pathol.* 1999 May; 26(5):253-8.
3. Jih DM, Morgan MB, Bass J, Tuthill R, Somach S. Oncocytic metaplasia occurring in a spectrum of melanocytic nevi. *Am J Dermatopathol.* 2002 Dec; 24(6):468-472.
4. Patterson, J W., and M R. Wick. *Nonmelanocytic Tumors of the Skin. Fourth Series. Fascicle 4.* Washington DC: Armed Forces Institute of Pathology, 2006. 337-339.

**Author Information**

**Deba P. Sarma, M.D.**

Department of Pathology, Creighton University Medical Center

**Eric E. Santos, M.D.**

Department of Pathology, Creighton University Medical Center

**William J. Hunter, M.D.**

Department of Pathology, Creighton University Medical Center

**Zoran Gatalica, M.D., D.Sc.**

Department of Pathology, Creighton University Medical Center